

ACTUAL STATE OF THE ART ON THE KNOWLEDGE OF CARPAL KINETICS (and surgical implications)

Grippi G.M. - Rombolà V. - Pompilio D.

MO of Hand Surgery – UOA of Orthopaedics and Traumatology San Lazzaro Hospital of Alba (CN) ASL 18 of Piemonte - Italy

Introduction: To realize the carpal kinetics is an essential knowledge in the clinical-surgical judgment. In literature, the carpal physiology has been an enigma replaced by uncertain thesis. The carpal model of Kapandj (1974) - "The chain movement carpal model" Gilford (1943) - "The columnar carpal model" Navarro (1919) - "The geometry varying carpal model" Taleisnik (1976), - "The ring carpal model" Lictman (1981), etc. (Fig. 1) (1,2,3) - have disclosed real aspects without, nevertheless, to gather the intimate device of carpal structure (4) - (Fig. 1). The consequences have been the clinical and surgical approximation. This way, the STT arthrodesis (based on the columnar concept), the SL arthrodesis (based on the Kapandj-ring vision), the Scapho-Capitate and Lunate-Capitate arthrodesis, result dubitative to the controls (5). On the contrary, the aforesaid theses don't have explain the success of the first carpal row resection. Besides, the Carpal Instability (CI) has been misinterpreted: a mechanical concept defined with descriptive terms beginning from the DISI-VISI patterns of Linscheid (1972) (Fig. 2 - A). In fact, this vision does not contemplate, the proximal sub-luxation of capitate and, consequently, the dislocation of rotation carpal centre (Fig. 2 - B). In real, this mechanical fact qualifies CI and consents to define its dynamic forms, also.

Material and Methods: Recently, the mentioned gap seems to be reduced by means of Biarticular Concentric Carpal Mechanism (BCCM) – in agreement to accredited experimental, clinical-surgical and philogenesis data - with these modern concepts (6).

1) - Carpus is devised as a femur biarticular prosthesis in which the little-head is reproduced by - the capitate's head that, on scaphoid and lunate, it constitutes the enartrosic articulation of the Coxa Manus. The carpal condyle as a meniscus, contains it and warrants its mechanical stability (Fig. 3).

2) - During movement, the carpal condyle undergoes a torsion with focus in the capitate head. In the same point the radiocarpic-axle and hand-axle converge to constitute the rotation carpal centre (CR). The maintenance of this collimation is the categorical imperative of carpal stability and normal wrist function. This involves the equidistance of the capitate by the radio (unvariability of the carpal height) necessary to the static-dynamic firm grip (Fig. 4).

3) - The Coxa Manus disruption implicates radiocarpic-axle/hand-axle divergence and defines CI. In practice, the check of a static or dynamic displacement of capitate's head is patognomonic of CI (Fig. 2).

4) - In the clinic, CI is the most frequent syndrome following carpal lesions. For this, indifferently in the injured side, the mechanical symptoms are always the same. The pain is a proprioceptive defence activated when the fixity of CR is lost and that it manifests in various degree with weakness, tenderness, antalgic contracture and rigidity. The other secondary symptoms are correlated to the damage side and its temporal evolutions with, click, positiveness of the instability tests, swellings, nervous compressions, malalignments, artrosis, etc. In consequence, in injured wrist the principal surgical target is to obtain the restoration of radiocarpic-axle/hand-axle convergence or, says with other terms, the reposition, even if only substitutive, of the CR.

Discussion: The Coxa Manus Surgery (CMS) is the application of the aforesaid methodology (7): when restituito ad integrum is possible, to reset the CR is enough the osteosynthesis and/or the ligament reparation (f.e. in the fracture and/or scaphoid pseudoarthrosis or in SL dissociation, etc.); instead if this is impracticable, surgical solutions exist deduced by BCCM. In fact, since the carpus pivot is the Coxa Manus and since the carpal condyle is a meniscus, the importance of surgical recovery of damaged radiocarpic joint or disrupted first carpal row, is relative: both, to the limit, can be sacrificed. In alternative, to reset the CR, a valid option is "to simplify the carpal function" by concentration of movement on capitate head (or, if this is damaged, using a substitutive prosthesis) (Fig. 5 - 6). This way, according to the damage, the capitate head (or its prosthesis) can be articulated on the radius-lunate-emiscaphoid arthrodesis (Coxa Manus Reconstruction) with increment of physiological centre-carpic movement (Case 1 - Fig. 7 - 8) or directly substituted (Case 2 - Fig. 9 - 10) or can be articulated on the radio by the Substitutive center-carpic resection-arthroplastic (Case 3 - Fig. 11 - 12).

Conclusion: The application of CMS - to the SLAC / SNAC / SCAC wrist, to the failures and malunions of distal radius fractures, to the failures of the scaphoid non-union surgical treatment, to the damages following post traumatic treatment, to the collapsed Kienboeck, etc. - has gotten reliable and satisfactory clinical results (8).

References

- 1) Kapandj IA. Fisiologia articolare 8vol. I, Soc. Editrice DEMI, Roma 1974.
- 2) Lichtman DM, Taleisnik J, and Watson K: Symposium on Wrist Injuries. Contemp. Orthop. 4:1, 107-144,1982.
- 3) Cooney WP, Linscheid RL, Dobyns JH: The Wrist diagnosis and operative treatment Vol.1, II. St. Louis ed. Mosby 1998.
- 4) Craigen MA, Stanley JK: Wrist Kinematics: row, column or both? J Hand Surg (Br) 20:165-170, 1995.
- 5) Siegel JM, Ruby LK: A critical look at intercarpal arthrodesis: review of the literature. J Hand Surg (Am) 21:717-723,1996.
- 6) Grippi GM: Cinematica del condilo carpale con introduzione al Modello Carpal Biarticolare Concentrico (MBC) e sua applicazione al problema dell'instabilità carpale. Riv. Chir. Riab. Mano Arto Sup., 34 (3), 1997, 389-401.
- 7) Grippi GM, Pompilio D: Surgery in the Outcomes of Traumatic Wrist: Coxa Manus Surgery: Proceedings of 8th Congress of the Federation of the European Societies for Surgery of the Hand. Amsterdam, May 22-25,2002; 57-64 - Editor Steven Hovius - 2002 by Monduzzi Bologna, Italy.
- 8) Grippi GM: La ricostruzione della "Coxa Manus" Indicazioni e tecnica chirurgica. Riv. Chir. Mano - Vol. 40 (3) 2003.

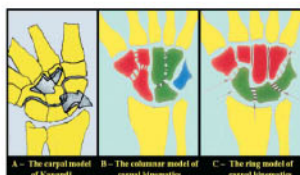


Fig. 1 The historical principal carpal models.

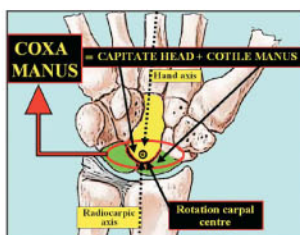


Fig. 3 The Coxa manus concept

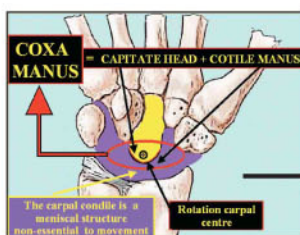


Fig. 5 - 6 In injured wrist, when restituito ad integrum is impossible, a valid option is "to simplify the carpal function" by concentration of movement on capitate head. In fact, since the carpal condyle is a meniscus and the carpus pivot is the Coxa Manus, surgical recovery of radiocarpic joint and/or first carpal row, is relative: both, to the limit, can be sacrificed. This is the reason of the success of first carpal row resection.

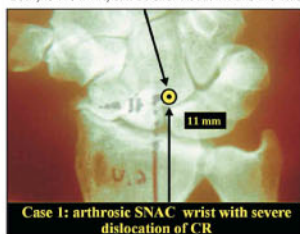

Fig. 7 - 8 Case 1 - (7) SNAC wrist, with severe dislocation of CR, treated by radius-lunate-emiscaphoid arthrodesis (8) Good result, four years post operation. The capitate's head has resacended of 3 mm and the recovered wrist motion is 80%.

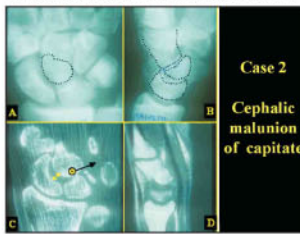


Fig. 9 - 10 Case 2 - 9(A,B) Malunion of capitate head in the right wrist. (C,D) The RM shows the disruption of Coxa Manus caused by capitate head sub-luxation and, in consequence, dislocation of CR. The clinical examination presents important algic-mechanical stiffness. 10(E,F,G) Treated by Coxa Manus Reconstruction using a substitutive capitate head prosthesis; (H,I,L) 25 months post operation, the complex recovered of carpal kinetics and wrist function is present.

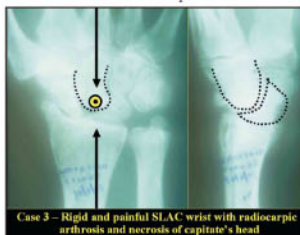


Fig. 11 - 12 Case 3 - Using the substitutive capitate head prosthesis is possible to perform first carpal row resection in every way. In fact, in this rigid and painful SLAC wrist with radiocarpic arthrosis and capitate head necrosis (11), is possible to observe the good recovered of wrist function 30 months post Substitutive center-carpic resection-arthroplastic (12).

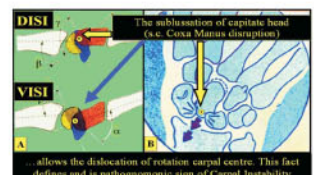


Fig. 2 A) The historical description of Carpal Instability, by Linscheid, does not contemplate the dislocation of CR.

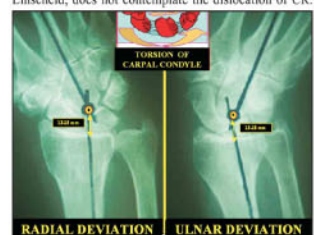

Fig. 4 The radiocarpic and hand-axle converge in the capitate head to constitute the Rotation carpal centre.

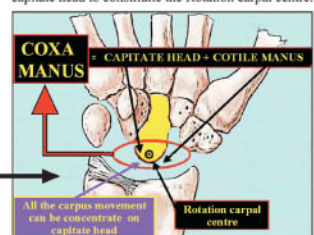


Fig. 5 - 6 In injured wrist, when restituito ad integrum is impossible, a valid option is "to simplify the carpal function" by concentration of movement on capitate head. In fact, since the carpal condyle is a meniscus and the carpus pivot is the Coxa Manus, surgical recovery of radiocarpic joint and/or first carpal row, is relative: both, to the limit, can be sacrificed. This is the reason of the success of first carpal row resection.

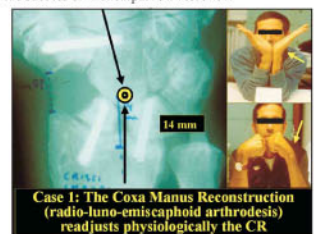


Fig. 7 - 8 Case 1 - (7) SNAC wrist, with severe dislocation of CR, treated by radius-lunate-emiscaphoid arthrodesis (8) Good result, four years post operation. The capitate's head has resacended of 3 mm and the recovered wrist motion is 80%.

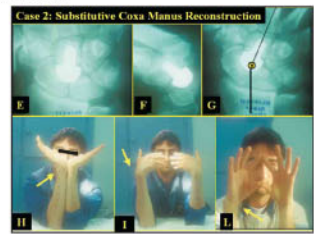


Fig. 9 - 10 Case 2 - 9(A,B) Malunion of capitate head in the right wrist. (C,D) The RM shows the disruption of Coxa Manus caused by capitate head sub-luxation and, in consequence, dislocation of CR. The clinical examination presents important algic-mechanical stiffness. 10(E,F,G) Treated by Coxa Manus Reconstruction using a substitutive capitate head prosthesis; (H,I,L) 25 months post operation, the complex recovered of carpal kinetics and wrist function is present.

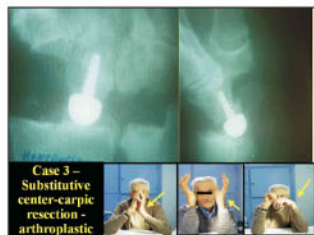

Fig. 11 - 12 Case 3 - Using the substitutive capitate head prosthesis is possible to perform first carpal row resection in every way. In fact, in this rigid and painful SLAC wrist with radiocarpic arthrosis and capitate head necrosis (11), is possible to observe the good recovered of wrist function 30 months post Substitutive center-carpic resection-arthroplastic (12).