

The Subcutaneous Three-compartment Fasciotomy in chronic Over-Use Syndrome of Forearm

GAETANO MAURIZIO GRIPPI

Hand Surgery in UOA of Orthopaedic, S. Lazzaro Hospital, Alba (Cuneo) - ASL CN2 of Piedmont, Italy, e-mail: gmrippi@libero.it, www.chirurgia-mano.org

SUMMARY

The present paper reports on the Subcutaneous variant of intervention of "Three-compartment Fasciotomy" (STF), a new surgical treatment to be used in chronic pancompartmental syndrome of forearm, particularly in the Over-Use Syndrome (OUS), that can be the result of repetitive muscular strains. 96 interventions, from 2009 to 2015, with a mean follow-up of 3.6 years, have been carried out. The results indicate that in over 95% of patients, the surgery was successful. Furthermore, this method, i.e. mini-open (by a sub-cutaneous surgical access), is simple, without contra-indication and, in our case study, has proved to be quite resolute.

KEY WORDS

Three-compartment Fasciotomy; Subcutaneous variant; forearm compartments; Over-Use Syndrome.

Received xx.xx.2016; accepted xx.xx.2016; printed xx.xx.2016

INTRODUCTION

The Subcutaneous variant of intervention of "Three-compartment Fasciotomy" (STF) (PHILIPS ET AL., 1986; FRY, 1988; QUINTNER, 1992; CHRISTEL & ROULOT, 1994; SÖDERBERG, 1996, GRIPPI, 2007) is a new surgical treatment to be used in chronic pancompartmental syndrome of forearm, particularly in

the Over-Use Syndrome (OUS), that can be the result of repetitive muscular strains (RUBINO & PETTINATI, 1994; COLOMBINI ET AL., 1996).

MATERIAL AND METHODS

The man's upper limb morphogenesis in phylogeny, adapted to the handling and use of instruments in various work activities, leads to attribute a primary causal role to the occupational factor (Over-Use) in the development of "overload disorders" (Fig. 1).

Overloading can also become cumulative in the course of normal business activities: in agriculture, in factories, in offices, at home, etc. An unrecognized overuse mode is vibration; for example, in professional riders or the users of vibrating tools (percussion, rotation, etc.).

The excessive Effort, the Repetitiveness, the abnormal Posture, the Vibrations, poor Rest can express themselves with enthesitis, tendinitis, teno-muscular breakage, early arthritis, neuropathies and mainly with the suffering for the forearm compartment. Especially, with clinical appearance of Chronic Compartment Syndrome of the anterior compartment of the forearm, which we identified and studied (see GRIPPI ET AL., 1997).

CHRONIC COMPARTMENT SYNDROME OF THE ANTERIOR COMPARTMENT OF THE FOREARM

Very schematically, the following types can occur:

1) - Tenderness on lacertus fibrosus or at the origin of the flexor carpi ulnaris sometimes with positive electromyography (EMG) ulnar nerve compression at the elbow.

2) - Tenderness on the flexor radialis carpi or flexor tendons in medium forearm often followed by the Carpal Tunnel Syndrome.

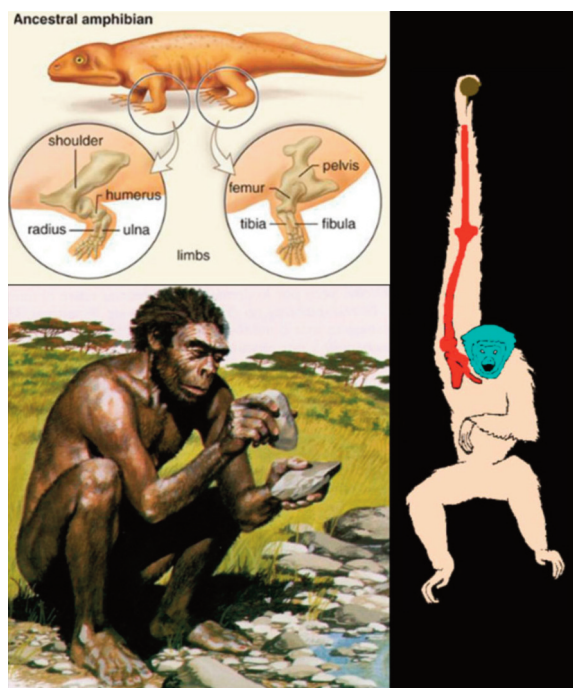


Figure 1. The man's upper limb morphogenesis in phylogeny.

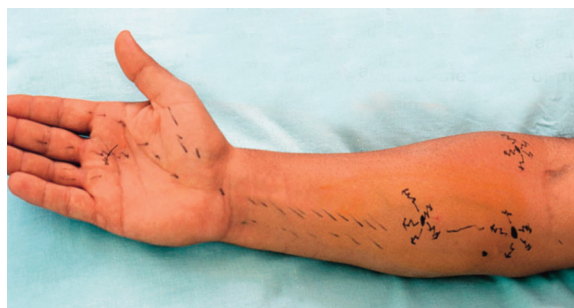

Figure 2. Forearm hypertrophy type "Popeye".

3) - Tenderness on the pronator teres, where the median neuralgia may take the form of the pronator teres syndrome or writer's cramp.

4) - In the form of medial or lateral epicondylitis, variously associated with radial ulnar or median neuralgia, with the suffering of all the three compartments of the forearm.

However, in the pan-compartmental suffering the pain dominates the clinic and often increases at night with neuralgia of the median, radial or ulnar compar-

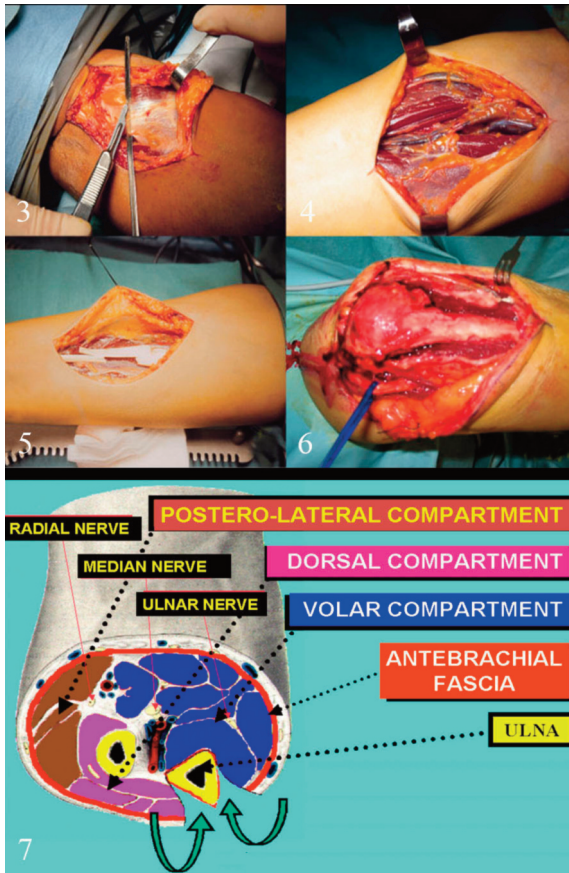
ments. Physical examination often shows an aspect of the forearm hypertrophy, type "Popeye" (Fig. 2).

Therapy should be considered to achieve immediate improvements, but also prevention is of great importance. To break the vicious circle, it's necessary to block the pathogenic process and allow recovery. This requires, as a first step, the suspension of all offensive activities with detection and correction of predisposing factors. The first approach is thus conservative with set-aside with guardians, prescription FANS, anti-edematous, vitamins, antioxidants; in some cases cortisone orally or infiltration and physiotherapy treatments (WITHESSIDE ET AL., 1975; PURAMEN & ALAVAIIKKO, 1981; MARTEUS ET AL., 1984; DETMER ET AL., 1985; KUTY ET AL., 1985; ANDERSON, 1988; PEDOWITZ & TOUTONUGHI, 1988; ALLEN & BARNES, 1989; WASILEWSKI & ARDOURION, 1991; SÖDERBERG, 1996; GRIPPI ET AL., 1997).

Surgical treatment is recommended in compartmental symptoms with nervous suffering and positive electromyography exam (PAGE, 1923; WITHESSIDE ET AL., 1975; PURAMEN & ALAVAIIKKO, 1981; CHRISTEL & ROULOT, 1994). Thus, according to the clinic, it may be carried out: section of the fibrous tendon (a), proximal fasciotomy of median (b), or neurolysis of the median to the carpal or cubital fasciotomy with ulnar neurolysis, or anterolateral fasciotomy (c), neurolysis of the radial (d). This, in order to implement the microcirculation in compartmental space (Figs. 3–6).

Because of the absence, in the past, of a specific surgical treatment for the associated suffering of all the compartments, in 2001 we designed and introduced the Three-compartment Fasciotomy (TF), published in 2007 (GRIPPI, 2007), in a study of 46 cases treated, with excellent results. The TF main indications are (GRIPPI, 2007): tenderness on palpation simultaneously present on epitrochlear and epicondylus and EMG indicating a nerve suffering of the median and/or ulnar. The TF rationale considers that the antebrachial fascia covers the three compartments of the forearm, with the ulna inserting at sides. Taking this into account, you can not unpack all the compartments with a single retro-olecranon cut, both rather is possible to cut through the antebrachial fascia on the ulnar margin, detaching the muscles at the sides (Fig. 7).

Figure 8 shows the typical Three-compartment fasciotomy by the original surgical access, as you can see on the right are visible the ulnar nerve freed and ulnar crest skeletonized. On the contrary, the Three-compartment fasciotomy sub-cutaneous mini-open access is characterized by two incisions: the first, of 3 cm, frees the ulnar cubital tunnel; the second, 1.5 cm, is centered on the ridge of the distal



Figures 3–6. Surgical Therapy in order to implement the microcirculation in compartmental space (see in the text). Figure 7. Three-compartment fasciotomy (muscle-fascia detachment from ulnar posterior crest).

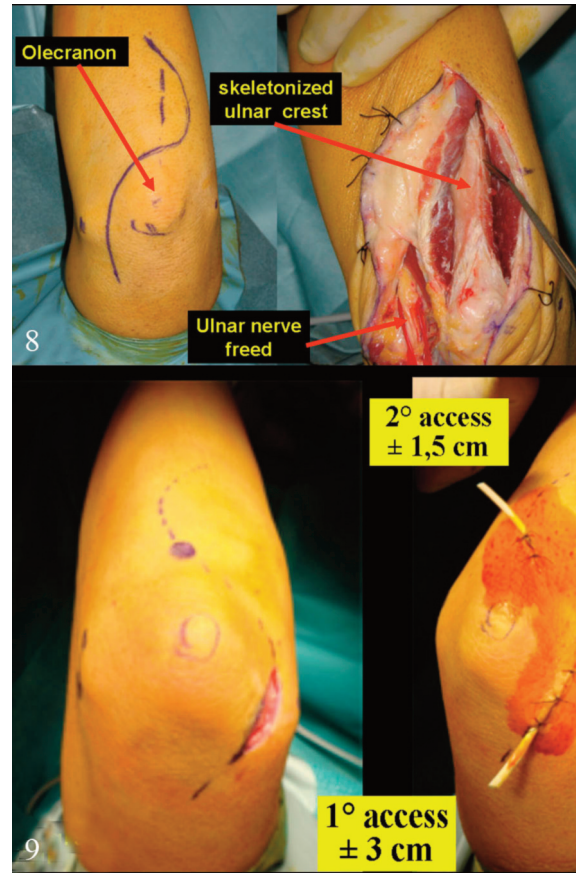


Figure 8. Three-compartment fasciotomy: open surgical access. Figure 9. Three-compartment fasciotomy: sub-cutaneous surgical access.

ulnar olecranon (Fig. 9). The contemporary decompression of the three compartments is performed with myo-fascial disconnection by periostotomo, through the skin incision (Fig. 10). It results in reduction of surgical time, optimization of the compliance and, in particular, disappearing of previous rare muscle hernias and residual strength loss.

RESULTS

We checked 74 cases and 96 interventions, from 2009 to 2015, with a mean follow - up of 3.6 years. Patients were evaluated for 5 parameters BRSS, modified, taking into account the degree of satisfaction, residual pain, recovery of strength, scar, resumption of the previous activities. Results indicate that in over 95% of patients, the surgery was successful.

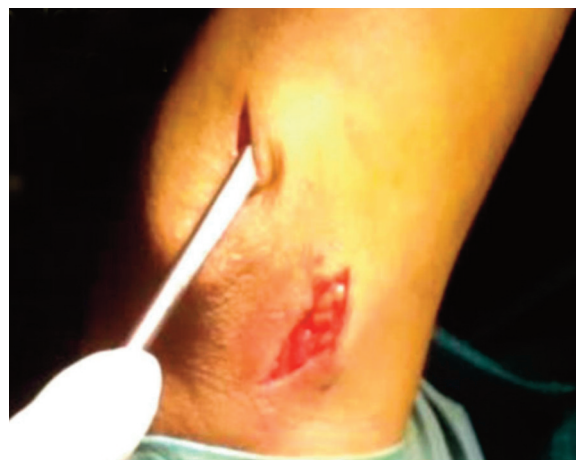

Figure 10. The periostotomo is slid under the skin on the sides and on the ulnar crest to detach the antebrachial fasce.

CONCLUSIONS

The OUS of the forearm is a diffused “work related disease” including several diseases generally considered independent from each other, but having the over-use as common cause. Proper drugs are the first step. If these don't resolve, the Three compartment Fasciotomy mini-open (sub-cutaneous surgical access) is simple, without contra-indication and, as discussed, in our case study, has proved to be resolute enough.

REFERENCES

- ALLEN M.J. & BARNES M.R., 1989. Chronic compartment syndrome of the flexor muscles in the forearm: a case report. *Journal of Hand Surgery [Br]*, 14: 47–48.
- ANDERSON R., 1988. Chronic compartment syndrome of the forearm extensor. *Lakartidningen*, 85: 218.
- COLOMBINI B., CRIECO A. & OCCHIPINTI E., 1996. Le attenzioni muscolo-scheletriche occupazionali da sovraccarico biomeccanico degli arti superiori. *Medicina del Lavoro*, 87, 8 (monograph).
- CHRISTEL P. & ROULOT E., 1994. Syndromes des loges. Appareil locomoteur. Editions Techniques. Encyclopédie Médico-Chirurgicale, Elsevier, Paris, 15-110-A-10: 12.
- DETMER D.E., SHARPE K., SUFIT R.E. & GIRDLEY F.M., 1985. Chronic compartment syndrome: diagnosis, management, and outcomes. *American Journal of Sports Medicine*, 13: 162–169.
- FRY H.J.H., 1988. Overuse syndrome and its differential diagnosis. *Journal of Occupational Medicine*, 30: 966–967.
- GRIPPI G.M., 2007. La fasciotomia tricompartimentale nella sindrome da sovraccarico funzionale cronico-dell'avambraccio. *Rivista di Chirurgia della Mano*, 44: 3–15.
- GRIPPI G.M., PERETTI G. & DETTONI A., 1997. Sindrome compartimentale cronica della loggia anteriore dell'avambraccio. *Rivista di Chirurgia della Mano*, 34: 243–252.
- KUTY J.E., SINGER R. & LINDSAY M., 1985. Chronic exertional compartment syndrome of the forearm: a case report. *Journal of Hand Surgery*, 10A: 302–304.
- MARTEUS M.A., BACKAERT M., VERMANT G. & MULIER J.C., 1984. Chronic leg pain in athletes due to recurrent compartment Syndrome. *American Journal of Sports Medicine*, 12: 148–151.
- PAGE C.M., 1923. An operation for relief of flexion - contracture in the forearm. *Journal of Bone & Joint Surgery*, 21: 233–234.
- PEDOWITZ R.A. & TOUTONUGH F.M., 1988. Chronic exertional compartment syndrome of the forearm flexor muscles. *Journal of Hand Surgery*, 13A: 694–696.
- PHILIPS J.H., MACKINNON S.E., MURRAY J.F. & MC MURTRY R.Y., 1986. Exercise - induce chronic compartment syndrome of the first interosseus of the hand. A case report. *Journal of Hand Surgery*, 11: 124–127.
- PURAMEN J. & ALAVAIKKO A., 1981. Intracompartmental pressure increase on exertion in patient with chronic compartment syndrome in the leg. *Journal of Bone & Joint Surgery*, 63A: 1304–1309.
- QUINTNER J.L. (Ed.), 1992. Overuse syndrome? *Journal of Bone & Joint Surgery*, 74B (2): 319.
- RUBINO G.F. & PETTINATI L., 1994. Patologia da sforzi ripetuti. C.T.S.7 - Atti Giornata di Studio ad hoc. Torino 23 giugno 1994. Assessorato alla Sanità Regione Piemonte.
- SÖDERBERG A. T., 1996. Bilateral Chronic Compartment Syndrome in the forearm and the hand. *Journal of Bone & Joint Surgery*, 78B; 780–782.
- WASILEWSKI S.A. & ARDOURION P.L., 1991. Bilateral chronic exertional compartment syndrome of forearm in an adolescent athlete: case report and review of literature. *American Journal of Sports Medicine*, 19: 665–667.
- WITHESSIDE T.E., THOMAS C.H., MORIMOTO K. & HIRADA H., 1975. Tissue pressure measurement as a determinant for need of fasciotomy. *Clinical Orthopaedics and Related Research*, 113: 43–51.